Clinical Technique for Class I Cavity preparation



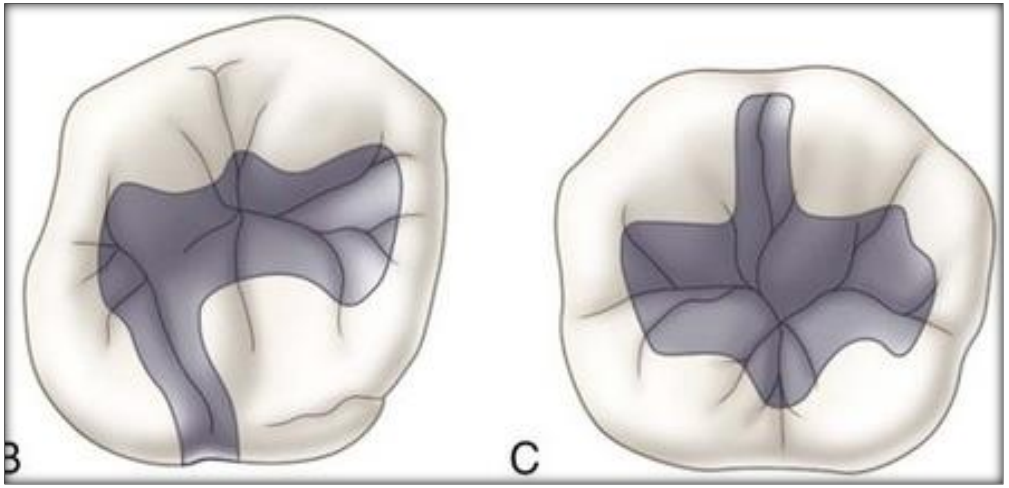

Prof.Inas Al-Rawi

Class I refers to

-Restorations on the occlusal surfaces of posterior teeth,

- The occlusal two thirds of facial and lingual surfaces of posterior teeth,

- The lingual surfaces of anterior teeth.

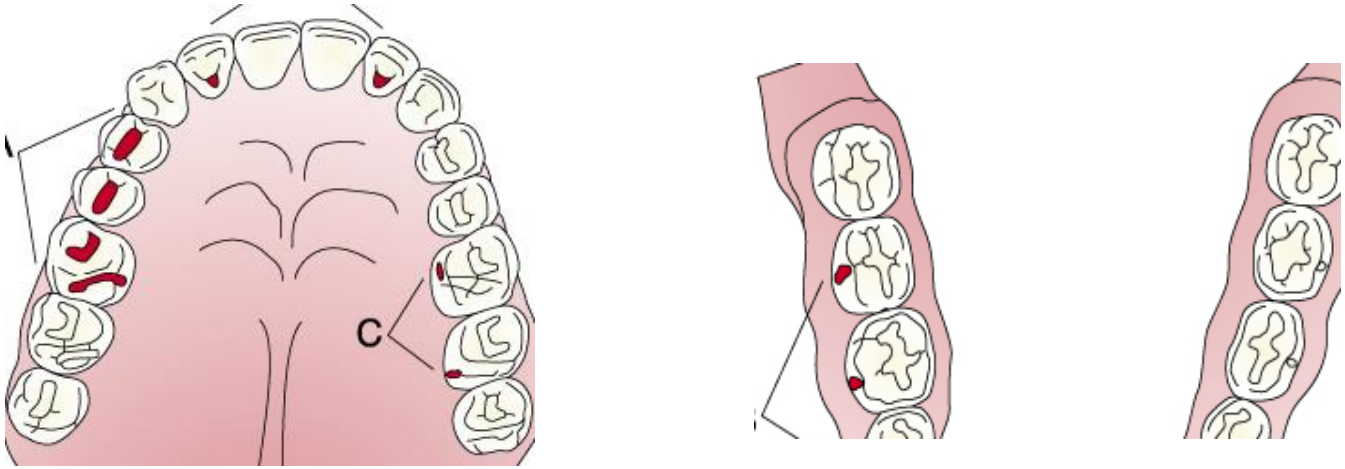

Cavity preparation of Class I

Outline form mean extension of the cavity to include:

1. Caries and decalcifications
2. Enamel unsupported by sound dentin
3. Pits and fossae, Major fissures and grooves
4. If the thickness of enamel between two preparation site is less than 0.5 mm, connect them to make one preparation, otherwise prepared as separate tooth preparations

5-maintaining the initial depth of 0.2-0.5 mm into dentin. though the actual depth of preparation may vary from 1.5 to 2 mm depending on steepness of cuspal slopes and thickness of the enamel



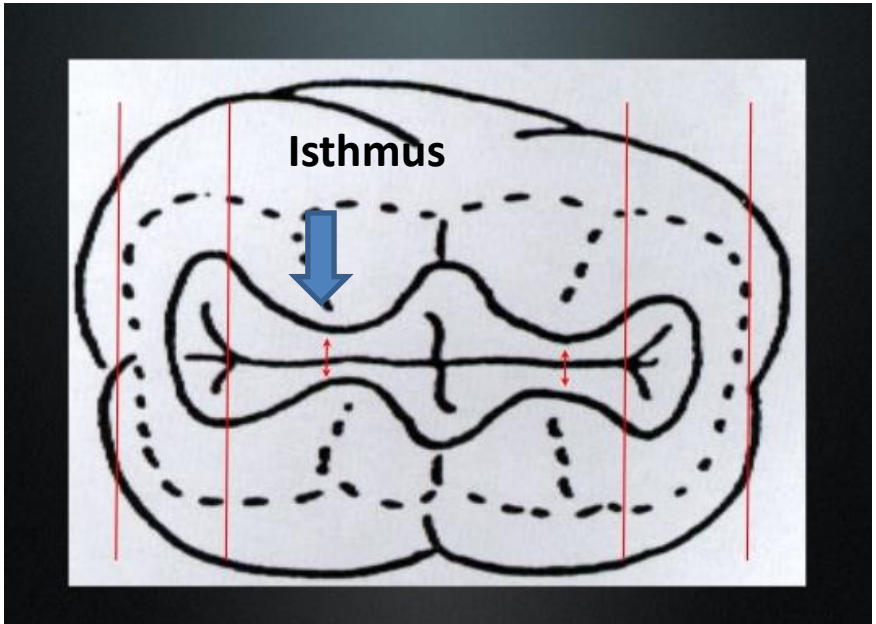

External outline form

• It should consist of smooth curves, and rounded line and point angles

• Enamel which is unsupported by dentin as well as the demineralized enamel should be removed since it is liable to fracture.



Internal outline form

• It includes the relationship of occlusal walls from cavosurface angle to the pulpal floor.

• Preparation depth should be at least 1.5 to 2.0 mm vertical from the cavosurface margin to the pulpal floor and at least 0.2 to 0.5 mm in dentin so as to provide adequate strength to resist fracture due to masticatory forces **(**

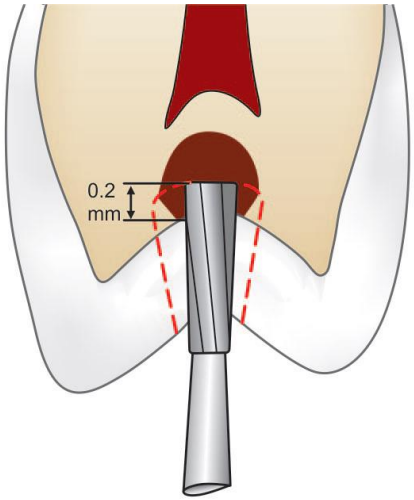

Figure -Preparation depth should be at least 1.5-2 mm
from the cavosurface margin and at least 0.2-0.5 mm into dentin

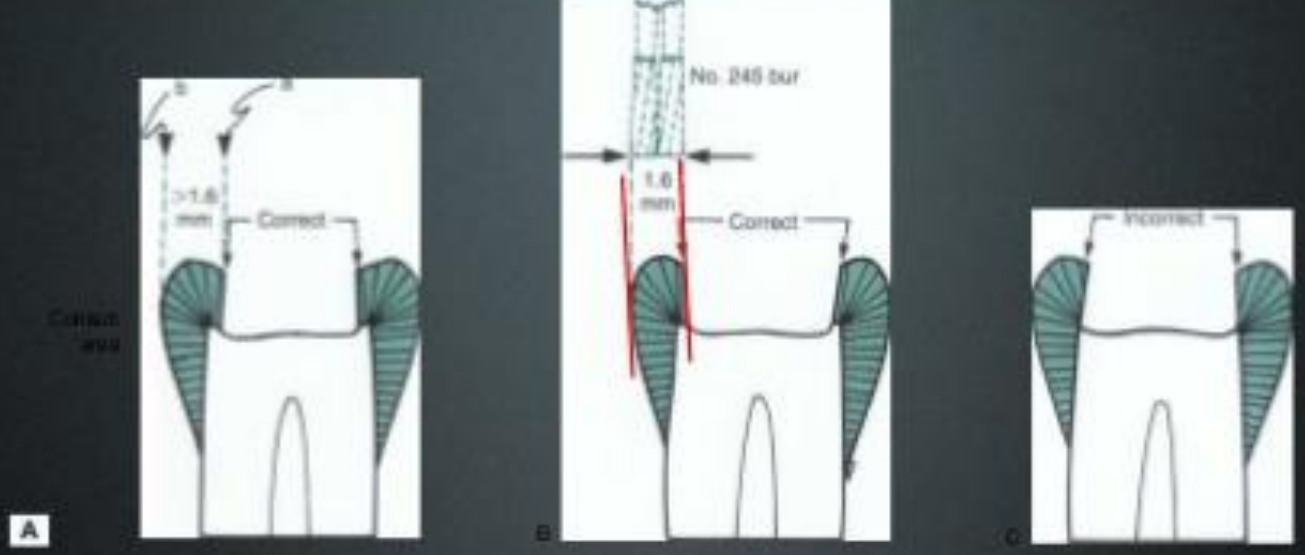

- To prevent the undermining of enamel at the marginal ridge, the mesial and distal walls should be parallel to the corresponding surface.

.Mesio-distal extension

1. Stop short of the marginal ridge crest.

to preserve strength of marginal ridges.

2. Parallel the contour of the marginal ridge

to preserve a uniform bulk (strength) to the marginal ridges.

3. If marginal ridge is unsupported or very thin it should be included, resulting in a Class II preparation. If not included the marginal ridge may fail (amalgam will be stronger than the unsupported enamel)

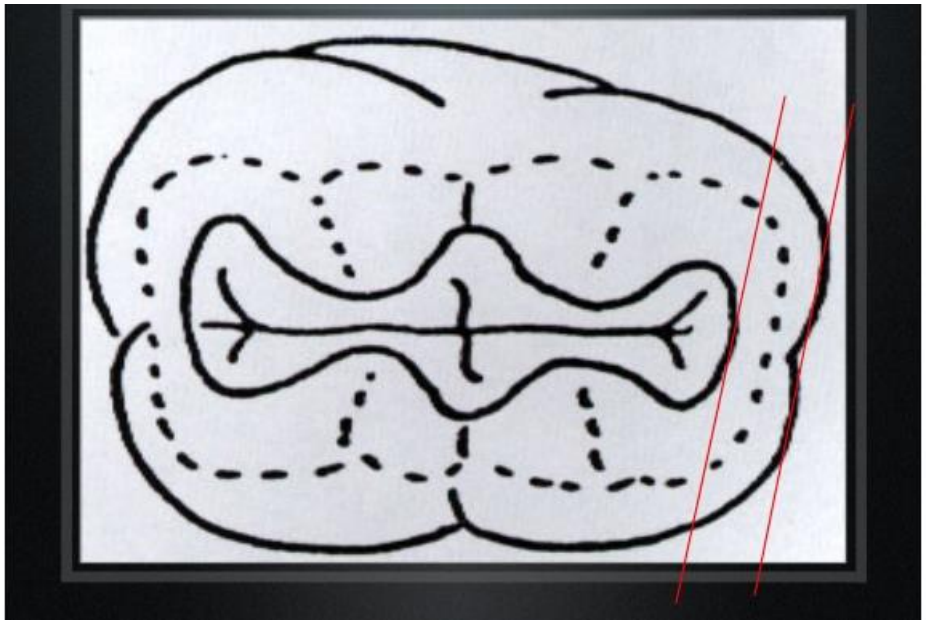

Obtaining Resistance

- Two consideration in resistance form:
  - the restoration must have adequate thickness and have a marginal design that will allow it to bear the forces without fracture or deform.
  - the remaining tooth st. must be left in such a state that it will resist the forces of mastication.

- Resistance form is provided by:
  - Sufficient area of relatively flat pulpal floor, to resist forces directed in the long axis of the tooth.
  - Minimal extension of external wall.
  - Strong, ideal enamel margins.
  - Sufficient depth.

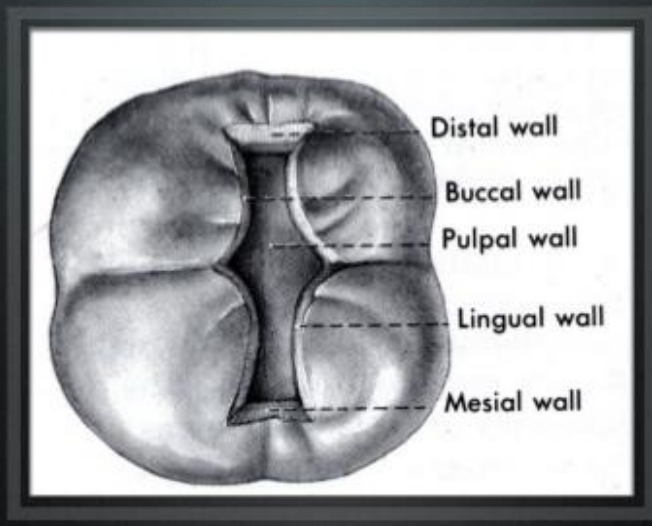

Removal of unsupported enamel by making the margin (90^0 -110^0) because less than 90^0 the tooth is more subjected to fracture.
if more than 110^0 lead to fracture of restoration.

Features of Resistance Form

Flat gingival and pulpal floors help in resisting masticatory forces directed along the long axis of the tooth, thereby prevent the tooth fracture from wedging forces resulting from opposing cusps.

- **Rounding of internal line angle to reduce the stress concentration points in tooth preparation)**

: Restrict the extensions of external wall so as to have strong marginal ridge area

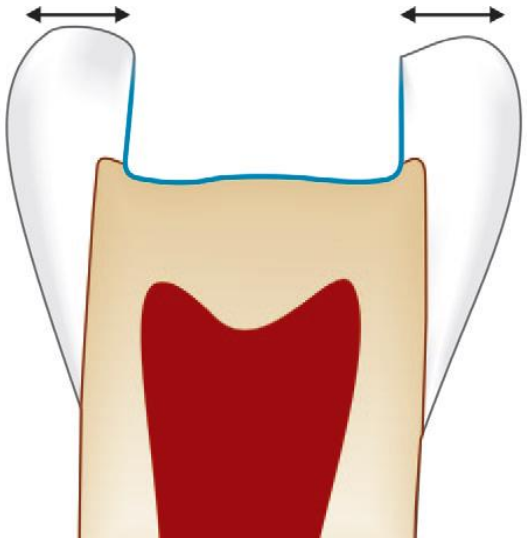

Restrict the extensions of external wall so as to have strong marginal ridge area

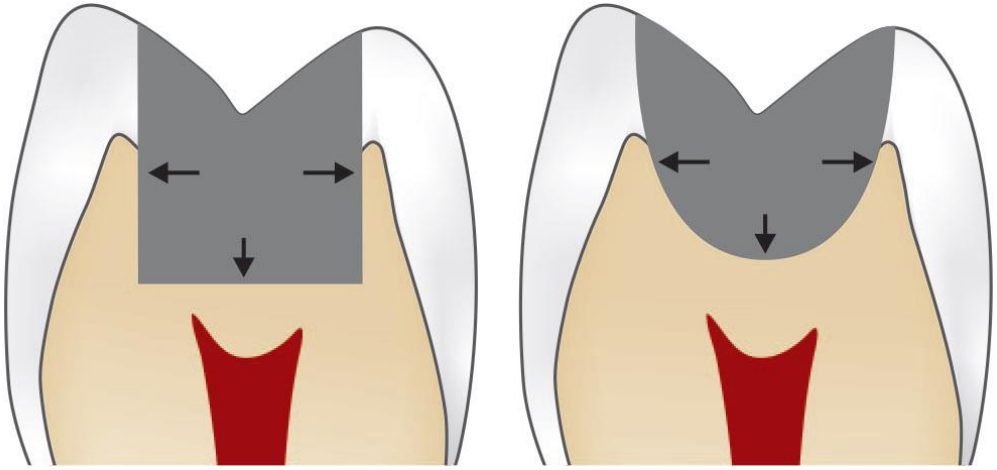

(A) Resistance form of tooth provided by flat pulpal floor; (B) In case of rounded pulpal floor, the rocking motion of restoration results in wedging force which may result in failure of restoration

Retention form: The parallelism or slight occlusal convergence of two or more opposing external walls , flat pulpal floor and 1/4 intercuspal distance provides the primary retention form.

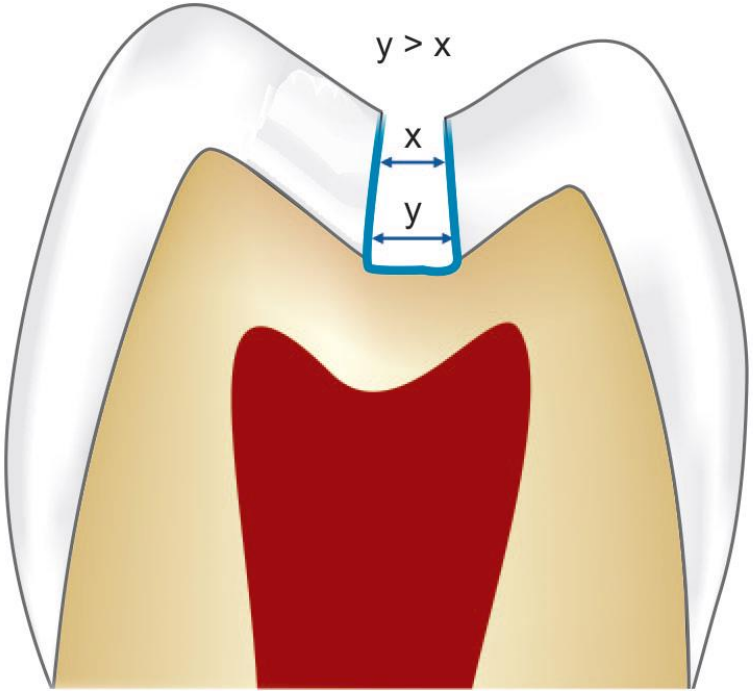

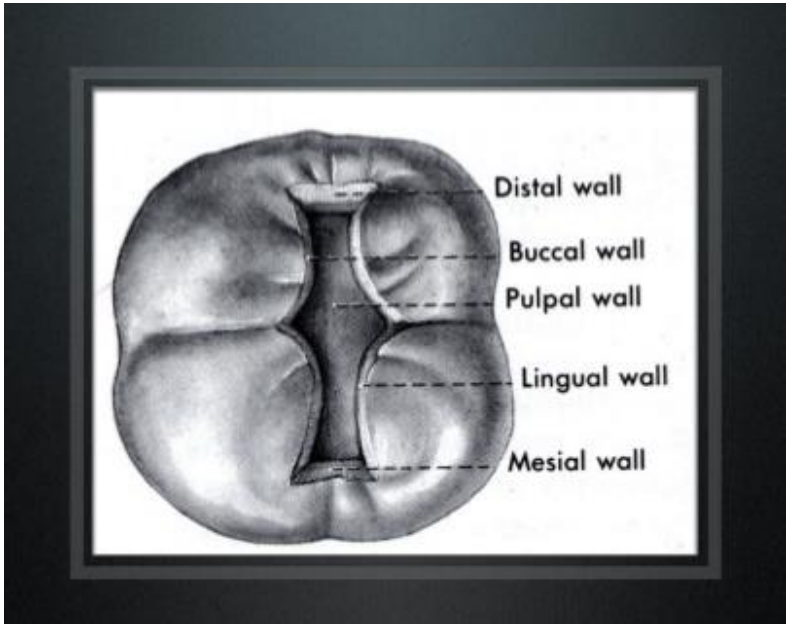

:B and L Preparation walls should have 2°-5° occlusal convergence for amalgam retention

Convenience Form





Is the shape of the cavity that allows an adequate observation, accessability this achieved by giving good depth (1.5-2mm) and width (1\4) intercuspal distance

Removal of Remaining Carious Dentin

- extension of the cavity should ensure, all caries is removed from the peripheral DEJ.
- In small size cavities, the carious dentin should have been removed during making the cavity extensions.
- Best removed using discoid-spoon excavator or a slow-speed round carbide bur of appropriate size.

. CAVITY FINISH

A.All Pulpo-occlusal line angles are round(no point angles are present) and follows general configuration of cavosurface outline.
increases retention of the amalgam restoration and preparation is more easily visualized.

B. Cavosurface margins 90-110 degree

1. Sharp (well defined)
easier to visualize and carve

2. Sound (well supported)
provides marginal integrity.

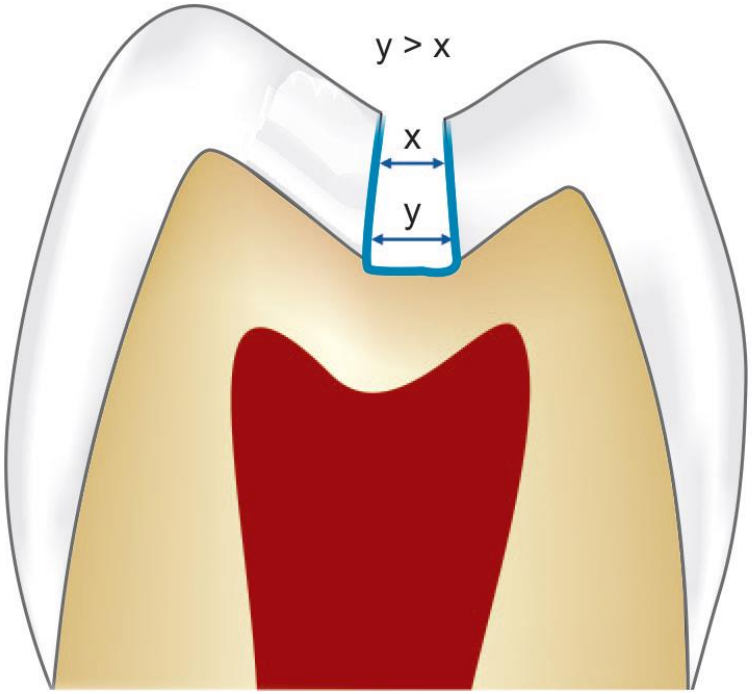

Cleansing of the Cavity

.– cavity is free of debris and moisture.

facilitates adaptation of amalgam to the cavity and improves the physical properties of the restoration by elimination of void or foreign material.

Buccal/ palatal Pit

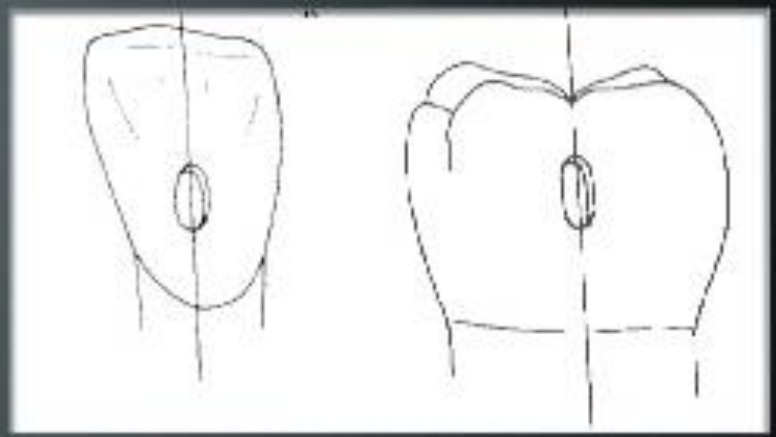

- Shape varies (oval - round - oblong) depending on the caries extension.
- Walls continually joined & slightly convergent towards the cavosurface margin.
- Axial wall follows the contour of the buccal/lingual surface.

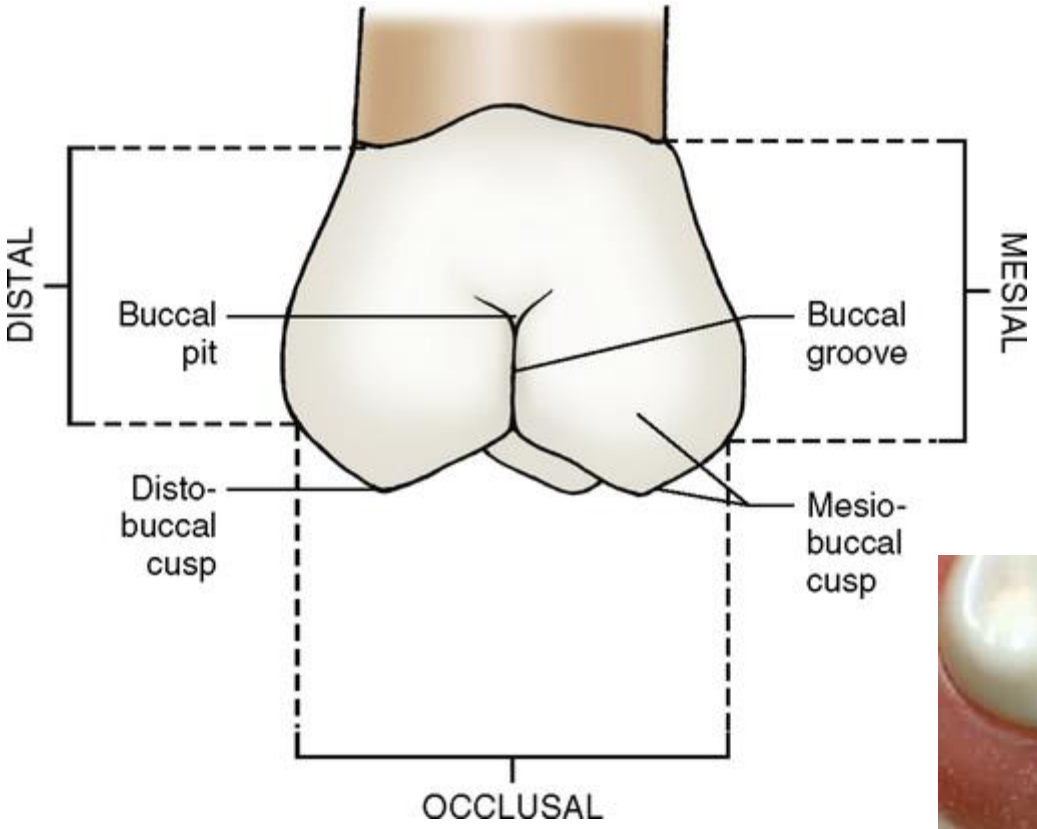
DISTAL
MESIAL
Buccal pit
Buccal groove
Disto-buccal cusp
Mesio-buccal cusp
OCCLUSAL



Occlusal pits of mandibular firstpremolars

Mandibular firstpremolars have 2 exceptions:

•If the central fissure is not involved by caries and because of the presence of well-developed transverse ridge two separated cavities one on mesial occlusal pit and one on distal are prepared, without including central fissure(in order not to weaken the tooth). However, if the central fissure is involved by caries then all pits and fissures are included.

•The buccal horn of pulp is higher than the lingualone. Therefore, the cavity floor should be inclined lingualy (not flat)in ordernot to expose or harm the pulp.The cutting instrument is held so that its longaxis is parallel with bisector of angle formed by longaxis of tooth and the line perpendicular to plane drawn through facial and lingual cusp point.

•Then all the principles of cavity preparation for class I are applied, except flattening of pulpal floor.

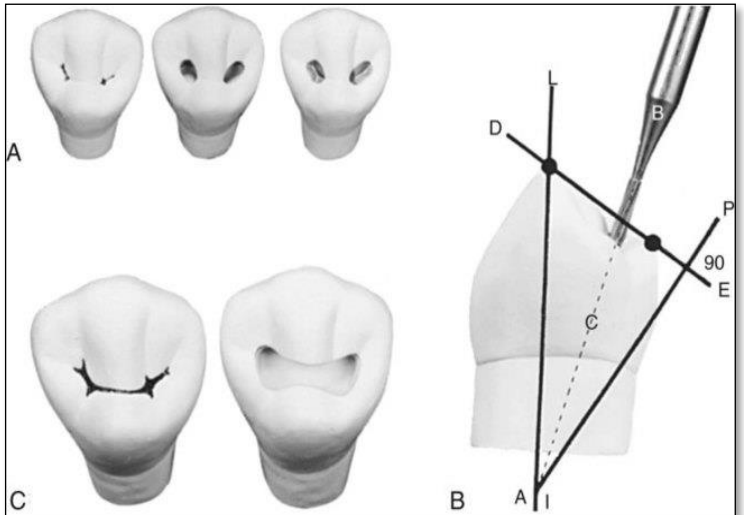

Cavity preparations for maxillary first molars

Maxillary first molar have an exception:

•The presence of oblique ridge between disto-buccal and mesio-palatalcusps gives the possibility to prepare 2 separated cavities one mesial and one distal without including the oblique ridge within the preparation unless it is involved by caries or weakened due to cavity preparat

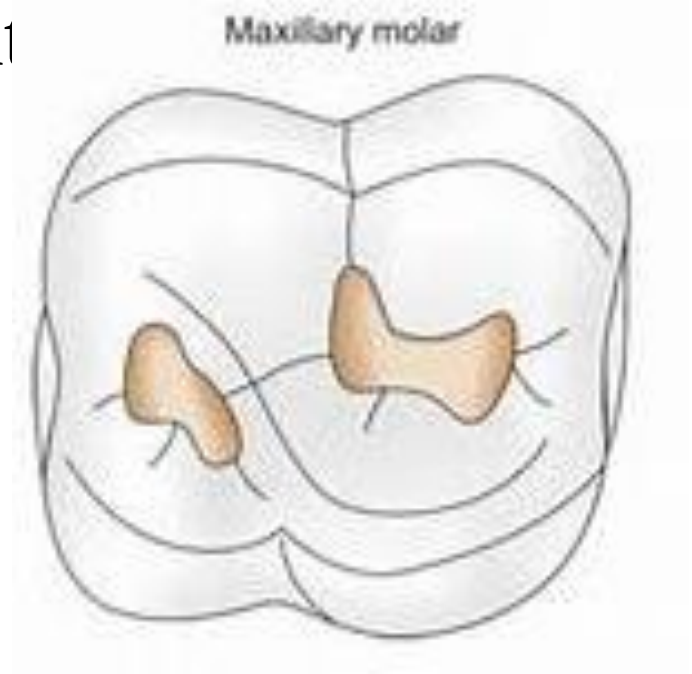

Compound Class I Amalgam Preparation

- When the Caries is extended into the lingual or palatal fissure.
- The outline is extended to include the affected fissure.





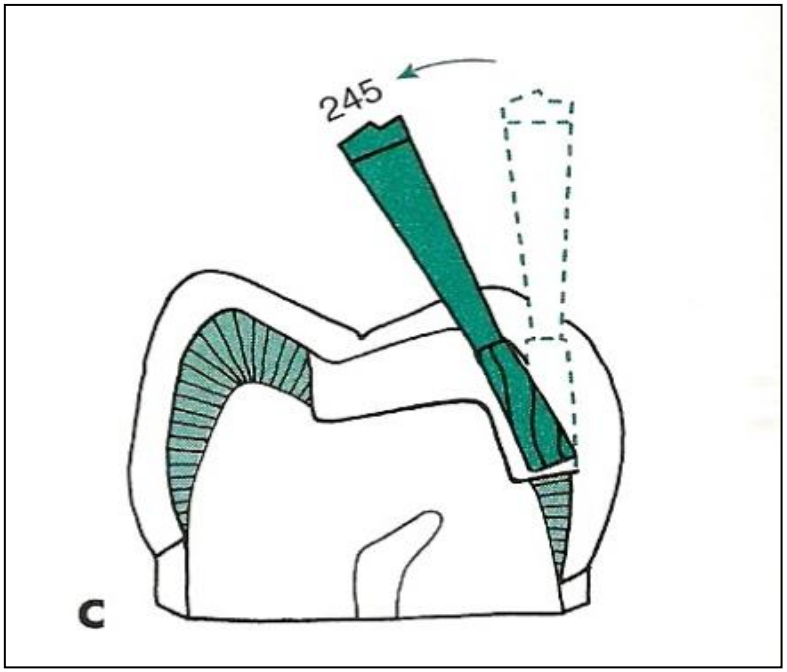

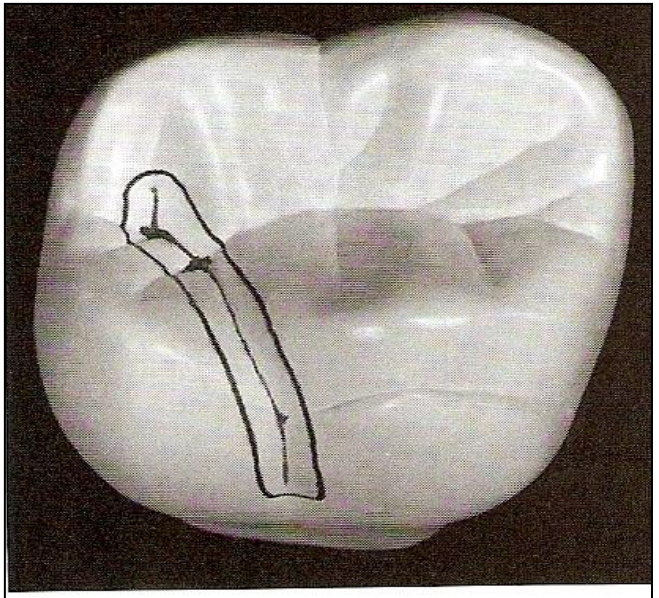

31 Outline of margins for OL tooth pre

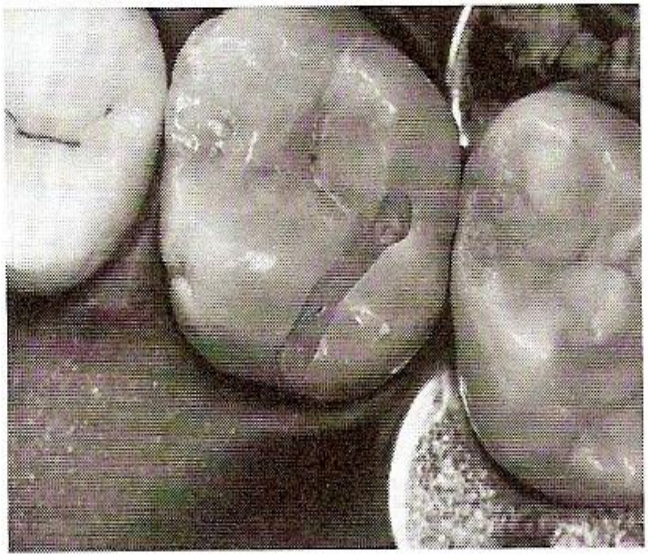

Any Question?