BASIC ANATOMICAL TERMS

DR ZAID O IBRAHEEM

Anatomy

- Anatomy is the study if the internal parts of the body and the relation among each other

Types of anatomical terms

1- Directional terms

2- Regional terms

3- Terms for the parts of the body

4- Imaging terms

Directional terms

Most of the directional terms refer to two opposite directions

Superior

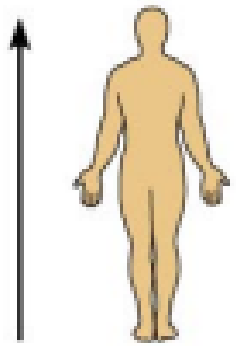

Refer to parts **above** the other

Or

closer **to head (cranial parts)**

Or

Parts **above the abdomen**

Vs

X

Inferior

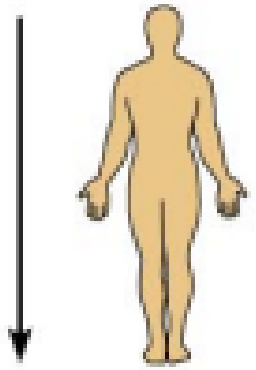

Refer to parts **below** the other

Or

Closer **to feet (caudal parts).**

Or

Parts **below** the abdomen

DIRECTIONAL TERMS

Anterior (Ventral)

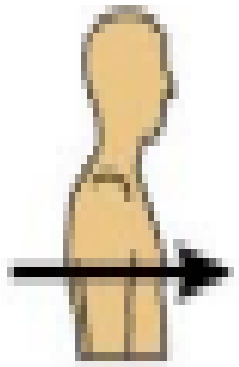

Vs

Posterior (Dorsal)



Toward the **front**

Example

The eyes are anterior to the brain

The breast bone is anterior to the spine

Ventral refer to the belly or the inferior surface of the four-legged animals

X

Toward the **back**

Example

Pharynx is posterior to the oral cavity

Directional terms related to the midline

The imaginary midline divides the body into two equal right and left halves

Medial

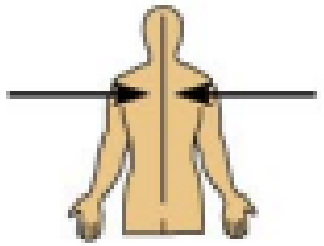

Toward the Imaginary midline of the body

Example

Nose is medial to the eyes

Intermediate



Between a more medial and a more lateral structures

The collarbone is intermediate between shoulder and the breastbone

Lateral

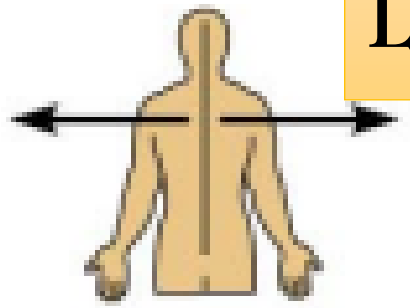

Away from the imaginary midline of the body.

Example

The ears are lateral to the eyes.

DIRECTIONAL TERMS

Ipsi-lateral

Contra-lateral

Vs

In the same side

Example

Both of the spleen and the descending colon are ipsilateral

The breast bone is anterior to the spine

X

In the opposite site

Example

Both of the spleen and the ascending colon are contralateral

DIRECTIONAL TERMS

Proximal

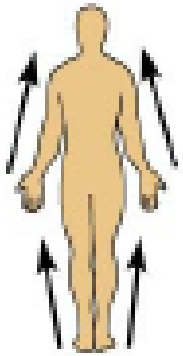

Describe a part closer to the trunk or to a specified reference point

Example

The elbow is proximal to wrist

Vs

X

Distal



Describe a part that is farther from the trunk or from a specified reference point

Example

The fingers are distal to the wrist

DIRECTIONAL TERMS

Superficial

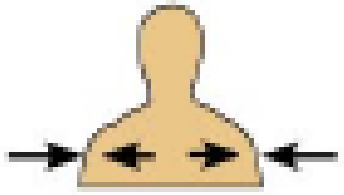

Situated outward or near the surface

Example

The skin is superficial to the skeletal muscles

Vs

X

Deep to or internal

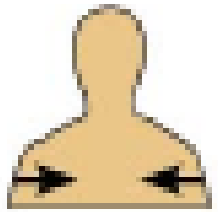

More internal

Example

The lungs are deep to the skin

Regional Terms

Terms that describe different regions of the body

DREGIONAL TERMS

Axial parts

Appendicular parts

Vs

Head + Neck + trunk

Limbs attached to body's axis

X

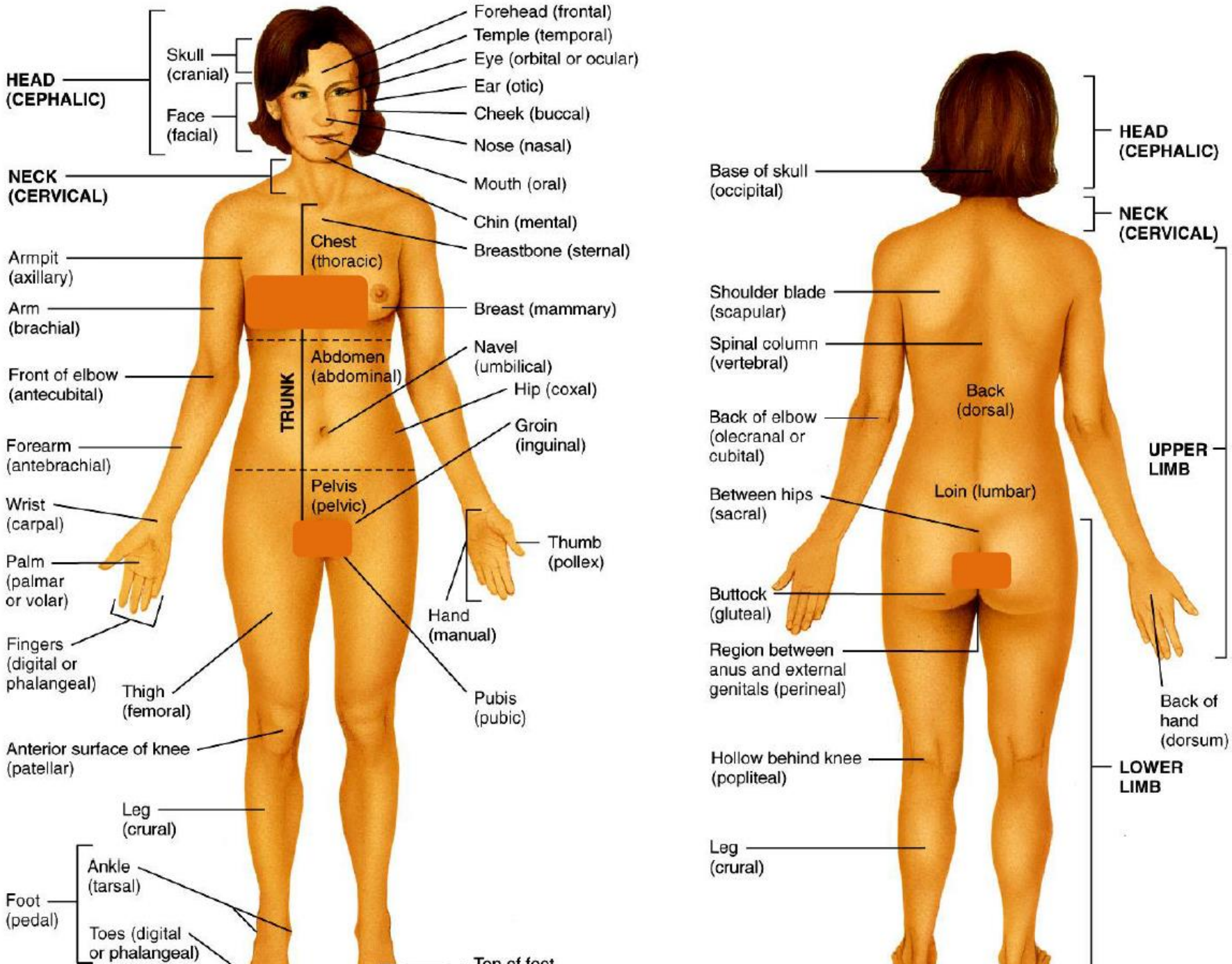
HEAD (CEPHALIC)
Skull (cranial)
Face (facial)
Forehead (frontal)
Temple (temporal)
Eye (orbital or ocular)
Ear (otic)
Cheek (buccal)
Nose (nasal)
Mouth (oral)
Chin (mental)
NECK (CERVICAL)
Chest (thoracic)
Breastbone (sternal)
Armpit (axillary)
Arm (brachial)
Breast (mammary)
Navel (umbilical)
Abdomen (abdominal)
TRUNK
Hip (coxal)
Front of elbow (antecubital)
Groin (inguinal)
Forearm (antebrachial)
Pelvis (pelvic)
Wrist (carpal)
Thumb (pollex)
Palm (palmar or volar)
Hand (manual)
Fingers (digital or phalangeal)
Thigh (femoral)
Pubis (pubic)
Anterior surface of knee (patellar)
Leg (crural)
Foot (pedal)
Ankle (tarsal)
Toes (digital or phalangeal)
Top of foot
HEAD (CEPHALIC)
NECK (CERVICAL)
Base of skull (occipital)
Shoulder blade (scapular)
Spinal column (vertebral)
Back (dorsal)
Back of elbow (olecranal or cubital)
UPPER LIMB
Between hips (sacral)
Loin (lumbar)
Buttock (gluteal)
Region between anus and external genitals (perineal)
Back of hand (dorsum)
Hollow behind knee (popliteal)
LOWER LIMB
Leg (crural)

Body planes

- - Body planes are defined in reference to a human body in upright position

Body positions

- - Upright position
- - Reclining position which may be supine or prone
- - Prone position = body is lying with face down
- - Supine position = body is lying with face up

Body planes

- 1- Transverse, axial, horizontal plane or cross sectional
  - A plane parallel to the ground and divides the body into supe
    feet) parts
- 2- Coronal, frontal or lateral plane
  - A plane perpendicular to the ground and divides the body int
    posterior (toward the back or dorsal) parts
- 3- Sagittal
  - A plane perpendicular to the ground and divides the body into
    - A- Midsagittal that divides the body into two equal parts
    - B- Para siggital that divides the body into two unequal left and right parts.
- 4- Oblique plane
  - A plane at a diagonal angle between the

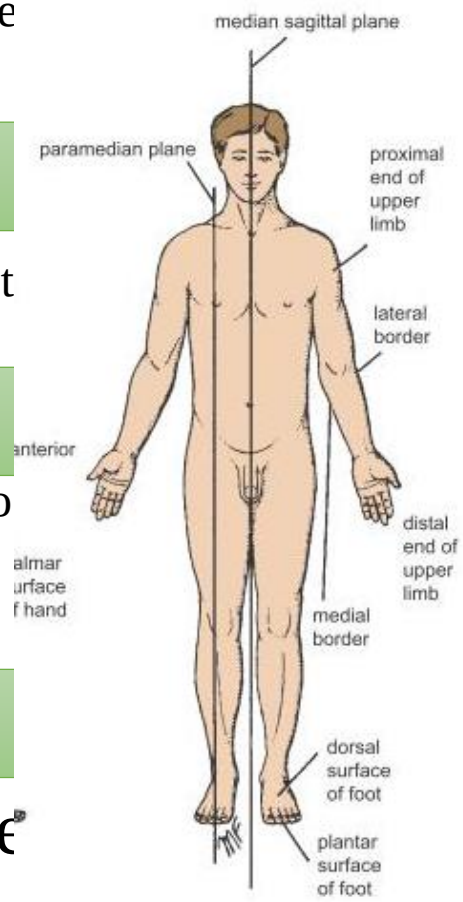

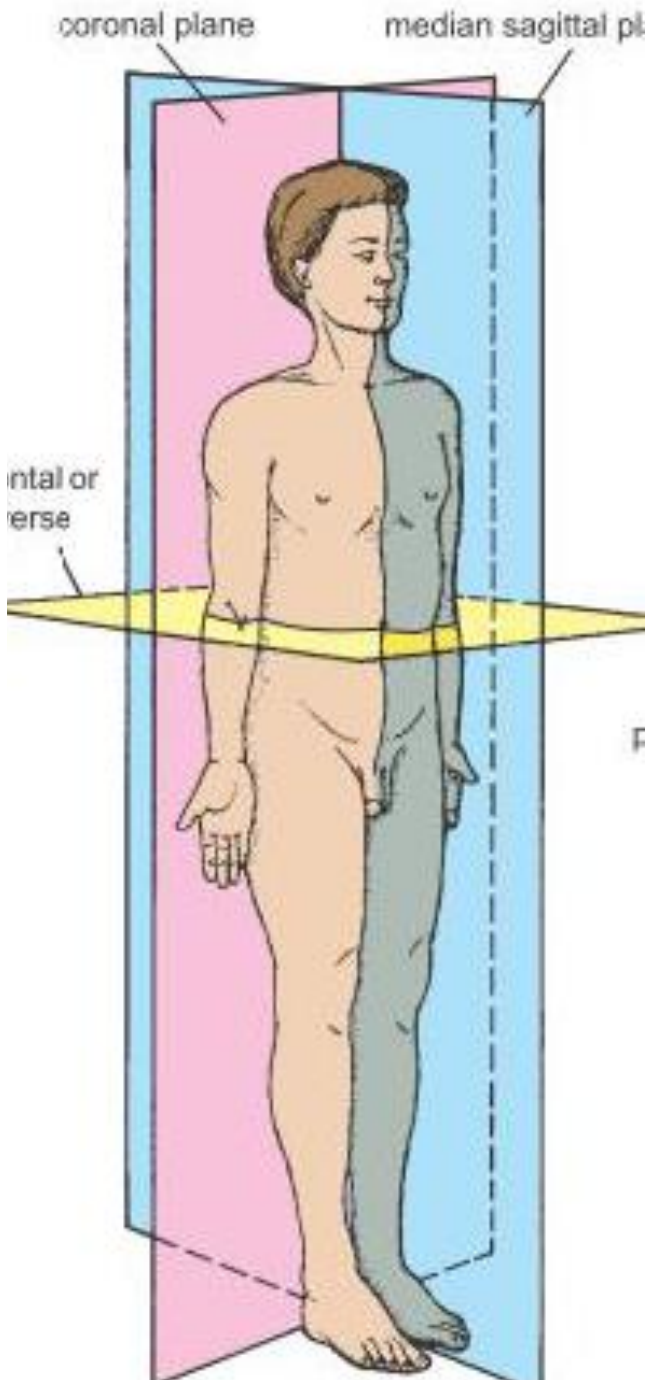

BODY CAVITIES

Cranial cavity = the cavity the is surrounded by cranium (skull)

Vertebral cavity = the cavity the is surrounded by the vertebral column and contains the spinal cord

Abdominal cavity = the cavity that contains GIT, kidneys and liver

Pelvic cavity = the cavity that contains urinary bladder, rectum and reproductive organs.

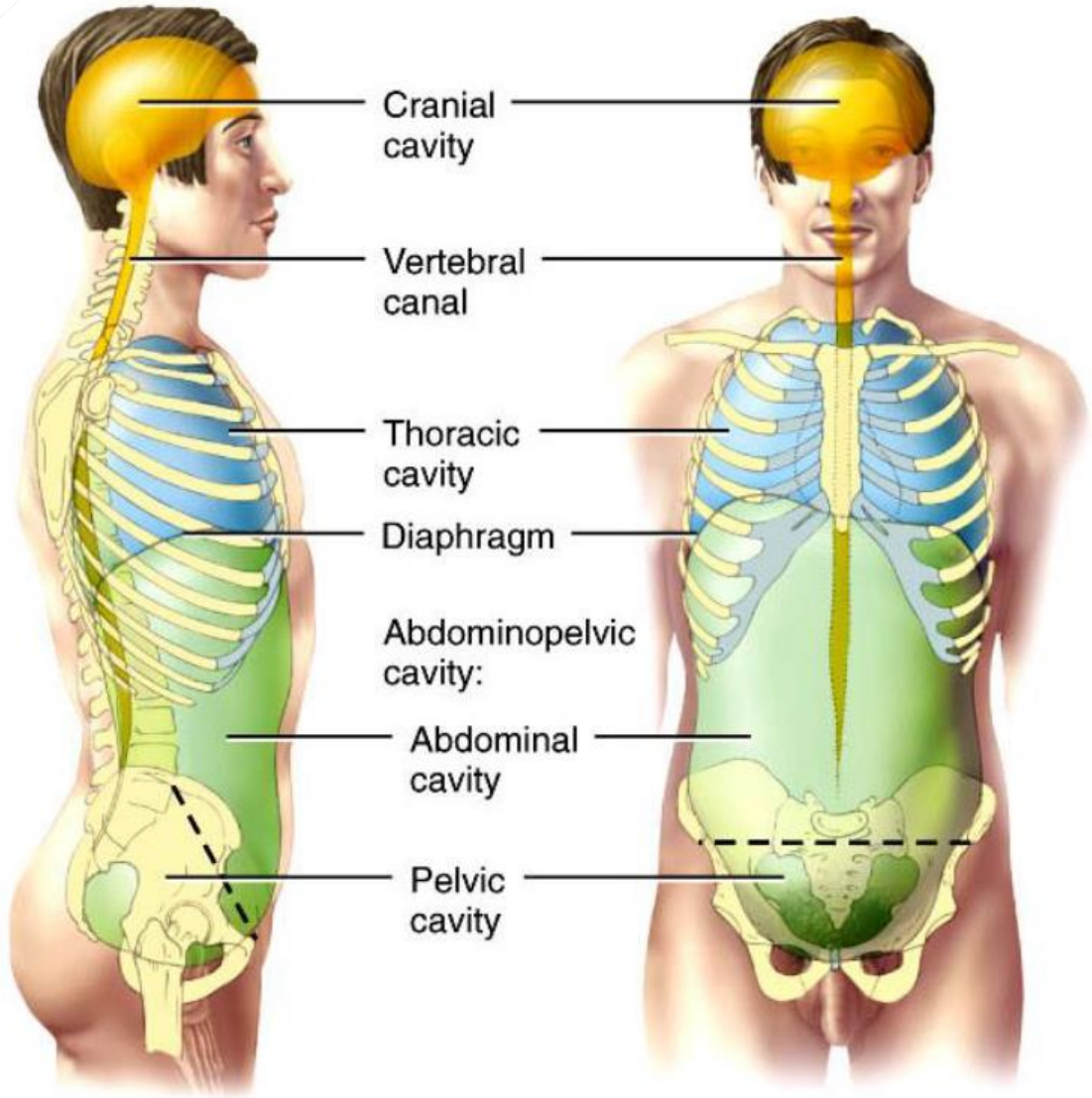

Body SYSTEMS

Dr Zaid O Ibraheem

Integumentary system (skin)

Musculoskeletal system (locomotive system)

Genital or reproductive system (male and female)

Nervous system

Endocrine system

Excretory system (urinary system)

Digestive system (Gastro-intestinal system)

Circulatory (cardiovascular system)

Respiratory system

TERMS RELATED TO THE NERVOUS SYSTEM

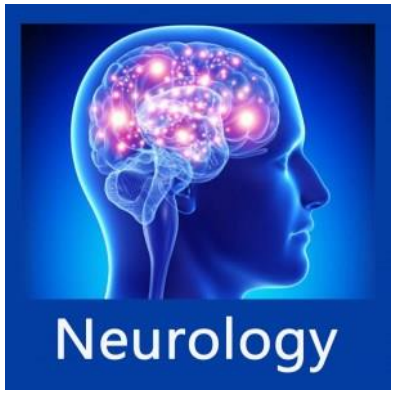

TERM	DEFINITION
Neurology	Neuro- means nerve.
	-ology is the study of.
	Neurology is a medical specialty that treats conditions related to the nervous system.
Neurologist	Neuro- means nerve.
	-logist means one who studies.
	A neurologist is a person who treats conditions related to the nervous system.
Neurosurgeon	Neuro- means nerve.
	Surgeon means a physician that treats deformities, injuries and diseases using operative procedures.
	A neurosurgeon is a physician that specializes in the nervous system and operative procedures.





MAIN PARTS OF THE NERVOUS SYSTEM

Encephal/o	brain
Cerebral-	brain

The brain is the portion of the central nervous system located within the cranium which is responsible for a person's intelligence, personality, reasoning, and their mood. It also allows a person to interact with their environment.

Crani/o	skull or cranium
-crania	head or skull

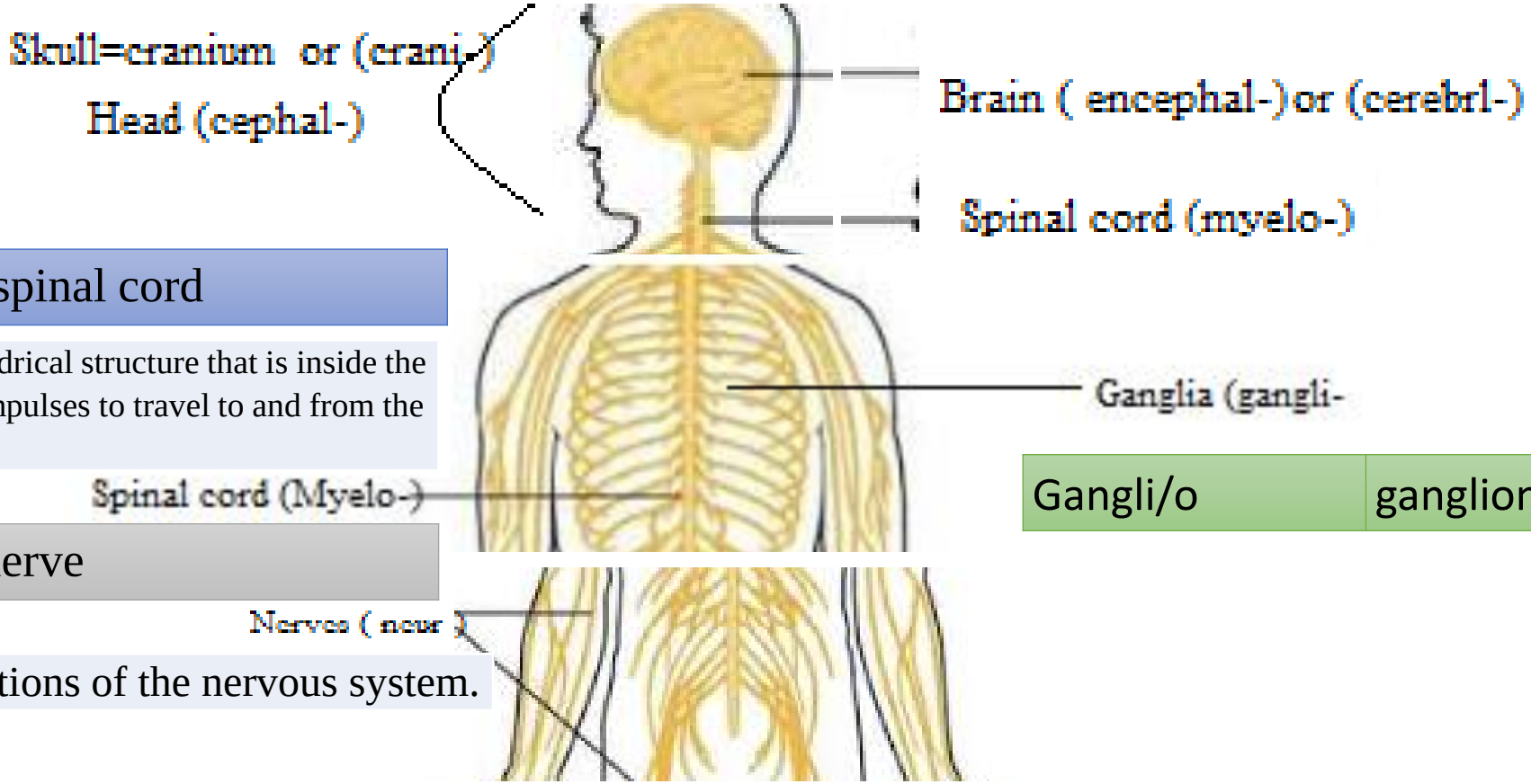

Myel/o	spinal cord

The spinal cord is located in a cylindrical structure that is inside the vertebral column. It allows nerve impulses to travel to and from the brain.

Gangli/o	ganglion

Neur/o	nerve

Neurons control all the functions of the nervous system.

Cerebral cortex
Cortex refers to the outer layer of a structure.
The cerebral cortex is a layer of neurons and synapses on the surface of the cerebral hemisphere.

Cerebrum
-cerebral means brain.
The cerebrum is the largest part of the brain.

Cerebellum
The cerebellum, located posterior to the brainstem, plays an important role in sensory and motor coordination and also balance.

Midbrain	The midbrain is the most superior portion of the brainstem.

Medulla oblongata
The medulla oblongata is the lowest portion of the brainstem. It is continuous with the spinal cord.

